

ALTERNATIVE THERAPIES

IN HEALTH AND MEDICINE

A PEER-REVIEWED JOURNAL · NOV/DEC 2009 · VOL. 15, NO. 6 · \$6.95

YOGA FOR CHRONIC LOW BACK PAIN · LOMI LOMI: A MASSAGE WITH MOVEMENTS
CAM WORKSHOP FOR MEDICAL STUDENTS · TREATING THE CAUSES OF DISEASE
PUTTING HEALING INTO HEALTHCARE REFORM · YEAR-END INDEX
ANTHROPOSOPHIC MEDICINE · CONVERSATIONS/BENJAMIN KLIGLER, MD



NARRATIVE REVIEW

TEMPORAL BONE MISALIGNMENT AND MOTION ASYMMETRY AS A CAUSE OF VERTIGO: THE CRANIOSACRAL MODEL

David C. Christine, CST

Objective • To describe dysfunction of the craniosacral system, particularly temporal bone motion asymmetry, as a cause of vertigo and to suggest a new perspective on research, diagnosis, and treatment.

Data sources • A database search was conducted using MEDLINE, CINHAI; Health Sources: Nursing/Academic Edition; and the Internet. Keywords: *vertigo diagnosis and treatment, craniosacral therapy, temporal bones, cranial bone mobility, Upledger, and temporomandibular disorders.*

Study selection • Articles that most clearly described a relationship between cranial bone misalignment and vertigo were selected for review.

Conclusion • Clinical experience suggests that craniosacral therapy is a powerful evaluative and treatment modality for vertigo patients who have not found relief from medical treatments. A narrative review of the literature describes and supports a theoretical link between dysfunction of the craniosacral system and vertigo. Dysfunction of the craniosacral system may include osseous, dural membrane, and fascial restrictions leading to asymmetric temporal bone movement and hence vertigo. Clinical trials are necessary not only to verify that craniosacral therapy is an effective treatment but also to determine the full range of symptoms and medical diagnoses for which craniosacral therapy is beneficial. (*Altern Ther Health Med.* 2009;15(6):38-42.)

David Christine, CST, works on a therapeutic team at Essential Therapeutics and Wellness, Stroudsburg, Pennsylvania.

The term *dizziness* is nonspecific but may refer to vertigo, lightheadedness, presyncope, disequilibrium, or other dizziness.¹ Vertigo is a type of dizziness characterized by sensations of movement (usually spinning) felt inside a person's head or perceived as the environment moving. Many conditions involving dizziness have overlapping symptoms; therefore, diagnosis with certainty is often difficult.^{1,3} Diagnoses in clinical practice are based mainly on patient history and symptoms, and patients are often vague or contradictory in describing their symptoms.² Agreement as to diagnostic terminology for various dizziness disorders varies.^{1,3} Symptoms can be quite variable among patients and within individual patients over time, creating a diagnostic challenge.

Most of those with chronic symptoms are not relieved by medical treatment.⁴ Undetermined and ill-defined causes of vertigo such as vasovagal syncope, hyperventilation syndrome, post-traumatic vertigo, and nonspecific dizziness are the most common single "cause" of dizziness reported.⁵ Many patients for whom the diagnostic process has failed may be erroneously diagnosed with a psychiatric problem.⁵

The lack of specific therapies for many types of dizziness has been called one of the "Achilles' heels in our ability to confidently ascribe etiologic labels."⁶ Likewise, establishing a cause of dizziness

is most useful when it leads to a specific therapy.⁷ Calls have been made for new approaches to diagnosis,^{1,3} and investigation of alternative therapies for chronic and recurrent dizziness has been advocated.¹ Patients, hospital-based physicians, and practitioners in primary care and medical subspecialties felt that they were not adequately informed about alternative treatments.^{8,9} Increased referral to alternative healthcare providers may require both ongoing peer-reviewed studies of efficacy and increased physician access to information concerning therapies that have undergone definitive study.⁹

The objective of this paper is to describe dysfunction of the craniosacral system,¹⁰⁻¹² particularly temporal bone misalignment,^{10,13-15} as a cause of vertigo and to suggest a new perspective on research, diagnosis, and treatment. The hypothesis presented here is that patients with asymmetrical temporal bone movement are likely to have some form of vertigo, dizziness, or imbalance, and there is a high likelihood that craniosacral treatment will relieve the symptoms if a temporal bone restriction is present. In this author's craniosacral practice, asymmetrical temporal bone motion has been found across a spectrum of dizziness patients who have not responded well to traditional medical treatments. Among the treatments that have not worked for these patients are meclizine, Vertigoheel (a homeopathic betahistine equivalent)¹⁶ prednisone, allergy treatment, Epley maneuver,¹⁷ physical therapy, vestibular rehabilitation, and chiropractic. The symptoms that have been resolved with the craniosacral technique include episodic spinning vertigo lasting hours, fluctuating hearing loss,

tinnitus, aural pressure, headaches, cyclical vomiting, motion intolerance, imbalance, positional vertigo, and autonomic symptoms associated with vertigo.

Dizziness patients, particularly those with spinning sensations accompanied by moderate-to-severe temporal bone asymmetry, generally find relief in a short time, usually within a few sessions. Successfully treated patients do not need medication, lifestyle changes, dietary restrictions, or vestibular rehabilitation. At this writing, no clinical trials have been performed to verify these claims; therefore, a review of literature was conducted to determine if there is evidence to support a theoretical foundation for craniosacral dysfunction as a cause of vertigo and perhaps to help bring some clarity to this often puzzling arena at least among a certain class of identifiable patients.

A database search was conducted using MEDLINE, CINAHL; Health Sources: Nursing/Academic Edition; and the Internet. Keywords used included *vertigo diagnosis and treatment*, *craniosacral therapy*, *temporal bones*, *cranial bone mobility*, *Upledger*, and *temporomandibular disorders*. Articles that most clearly described a relationship between cranial bone misalignment and vertigo were selected for review.

DISCUSSION

The craniosacral model¹⁰⁻¹² proposes a new way of evaluating and treating vertigo symptoms with the observation that the bones of the skull move in response to rhythmic pressure changes within the membranes surrounding the brain and spinal canal. Mobility restrictions or misalignments along the cranial sutures are said to have adverse effects on health that can be corrected through gentle manipulation of the cranial bones, sacrum, and the connecting membranes enclosing the brain and spinal cord. These structures also may be influenced through release of connective tissue tension anywhere in the body.

Proper functioning of the craniosacral system is evaluated through palpation of the craniosacral rhythm, the regular wave of fluid-pressure changes within the system, about 6 to 12 cycles per minute. The production phase of the cycle is termed "flexion" or filling cycle. The resorption phase is termed "extension" or draining cycle.

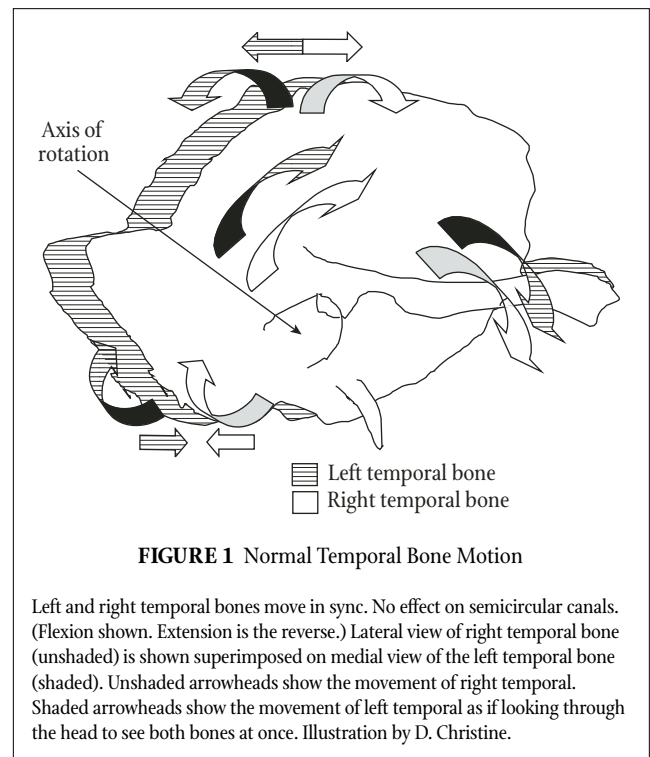
The craniosacral rhythm is transmitted to the sacrum via the dural tube and throughout the entire body via osseous connections, dural spinal sleeves, and the motor division of the nervous system. During flexion, the entire body externally rotates slightly; during extension, the body internally rotates. The craniosacral rhythm, therefore, may be palpated anywhere in the body. Restrictions in the body fascia can result from a variety of internal and external causes. These restrictions cause interruptions of the craniosacral rhythm, thereby revealing the location of the problem. The entire system constitutes a delicate and subtle pattern of energy ebb and flow that is responsive to gentle touch but resists heavy or intrusive touch.

Temporal Bone Motion and Dural Attachments

The 2 adherent layers of the dural membrane within the cra-

nium separate to form a horizontal leaf (the tentorium cerebelli) and a vertical leaf (the falx cerebri), thus dividing the brain into quadrants. When the system is filling during flexion, the skull widens and shortens. When the system is draining during extension, the skull narrows and lengthens.

The temporal bones are connected bilaterally along a roughly horizontal plane by attachments of the tentorium cerebelli. They move in tandem about diagonal axes roughly along the lines of the auditory canals. During flexion (Figure 1) the squamous portion of the temporal bones arc forward and lateral, increasing the distance between them. At the same time, the zygomatic processes move inferior. The mastoid tips move posteriorly, superiorly, and closer together. This movement is known as external rotation and causes the anterior borders of the tentorium cerebelli to move slightly anterior. The effect is to tighten the membrane, which acts as a diaphragm influencing the fluctuation of cerebrospinal fluid. During extension, cerebrospinal fluid-pressure decreases and the movements of the temporal bones reverse along the same axes. Thus, the general movement of the paired bones is forward and backward in an arc. But because the axis of rotation is along a diagonal axis, they also move inward and outward, something like a casement window swinging externally above and internally below its horizontal axis. This complex motion has frequently been compared to a wheel wobbling around a bent axle.



Dysfunctional Temporal Bone Movement

Impediments to normal temporal bone motion can occur anywhere along the arc of its normal motion. These impediments could stop motion completely at a certain point, disallowing

completion of the motion cycle in that direction, then return under normal rate and amplitude. Alternately, the impediment may simply cause a drag at that point that slows the motion but that is gradually overcome as the momentum carries the bone beyond the point of restriction. Such restrictions also may cause a jerky stop-start motion of the bones that could adversely influence inner ear fluid dynamics. Osseous compression of 1 or both temporal bones could result in little or no motion. Torsion in the dural membrane could cause a variety of abnormal wavy or wobbly motions.

If the movement of the temporal bones contradicts or over-accentuates fluid movement in the semicircular canals, the resulting sensory conflict may lead to the classic symptoms of motion sickness: pallor, sweating, hypersalivation, disorientation, nausea, drowsiness, and vomiting.¹⁸ One temporal bone moving anterior and lateral while the other moves posterior and medial (Figure 2) would produce not only asymmetrical neural inputs, inducing vestibular symptoms, but also could create the illusion of self-rotation with or without actual body movement.¹⁹ Spinning vertigo, in contrast to more vague sensations of dizziness, may thus be a result of the opposite motions of the bones on 2 sides of the head as if, in fact, the head were spinning.

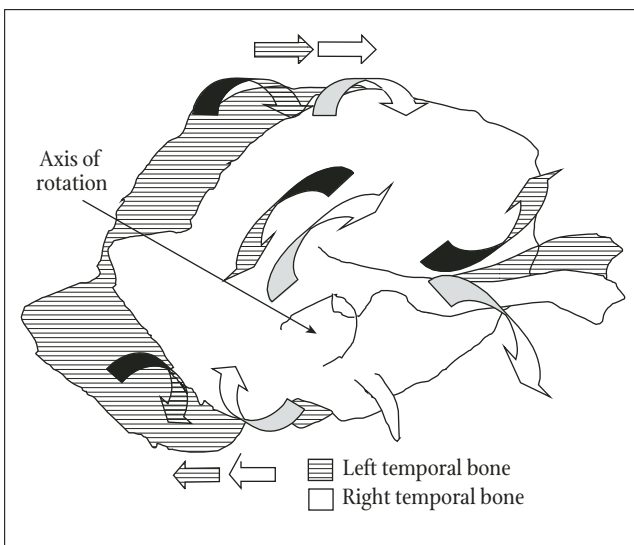


FIGURE 2 Dysfunctional Temporal Bone Motion

Bones move in opposite directions, theoretically causing contradictory neural inputs to semicircular canals. Lateral view of right temporal bone (unshaded) is shown superimposed on medial view of the left temporal bone (shaded). Unshaded arrowheads show the movement of right temporal. Shaded arrowheads show the movement of left temporal as if looking through the head to see both bones at once. Illustration by D. Christine.

Supporting Evidence

In the 1930s, osteopathic physician William Garner Sutherland, DO, observed that the speno-temporal suture was beveled like the gills of a fish and appeared to be designed for movement.¹³ Skulls with patent sutures have been described as complexes of independent units or functional components rather than isolated single structures.^{20,21} Slight movement has been

measured between the cranial sutures.²²⁻²⁹ The cranial sutures are innervated and highly vascularized but are not rigidly fused.^{30,31} Mechanical restriction of cranial bone movement causes measurable physiological responses, which abate when constriction is removed.²³ Cranial bones of rats transplanted to a new location changed the morphology of the suture (eg, butt-end to beveled overlapping)³² consistent with the functional demand of the new location for growth and movement.^{20,31,32} There is evidence that sutures are patent throughout life.³⁴⁻³⁶ Dural membranes can elongate upon application of traction of the cranial bones on an embalmed cadaver.³⁷ Dissection studies of fresh cadavers^{38,39} suggest that the dural membranes are capable of manipulation with light traction via osseous “handles.” Changes in cranial bone positions after cranial manipulation were measured in degrees using x-rays (Dental Orthogonal Radiographic Analysis).⁴⁰ Degree of change of the atlas, mastoid, zygomatic, sphenoid, and temporal ranged from 0° to 8°. The average degree of change for the mastoid was 1.66 (range 0-6).⁴⁰ The average degree of change for the temporal was 1.75 (range 0-5).⁴⁰ Measurements of strain on the skull using laser holography show strain patterns with as little as the weight of a penny.⁴¹ Distinct swirling patterns appear upon compression of the temporal bones with a pair of tongs.⁴¹ This pattern is consistent with reported palpated motion of the temporal bones classically described as a wobbly wheel.

Sources of Craniosacral Restriction

Clinical experience suggests that spinning vertigo, in contrast to the more vague complaints of dizziness and unease, is more likely to occur the more diametrically opposed the temporal bones move in relation to one another (Figure 2). Hearing loss, nausea, vomiting, and/or other autonomic symptoms with or without vertigo are more likely to occur when one or both temporal bones are compressed or moving sluggishly. Because the temporal bones have articulations with the sphenoid, occiput, parietals, and zygoma, misalignment of any of these bones could affect the entire cranium, causing any number of nerve entrapment pathologies, vascular occlusion, and interference with lymphatic channels.^{13,14,33,42}

This author has seen a patient who, in a single session, was completely relieved of episodic vertigo and hearing loss, tinnitus, and aural pressure along with nausea, pain in the left cheek, excess saliva, difficulty swallowing, and a bitter taste in the mouth by a craniosacral release of a compression at the left jugular foramen. Table 1 lists the nerves and blood vessels passing through the temporal bone, suggesting possible causes for these symptoms if the temporal bones are compressed or misaligned.

Temporal bone problems may result directly from osseous impaction or from dural tension on the bones that can be transmitted from anywhere in the body. The intracranial dural membranes are connected with the cervical fascia and so with much of the rest of the body.³³ For example, there is a direct continuity of fascia from the apex of the diaphragm to the base of the skull extending to the outer surface of the sphenoid, occipital, and temporal foramina. The fascia continues through the foramina at the

TABLE 1 Nerves and Blood Vessels Running Through the Temporal Bones

Acoustic	Internal carotid artery
Chorda tympani	Stylomastoid artery
Facial (C.N. VII)	Internal jugular vein
Greater petrosal	Occipital artery
Sympathetic plexus of internal carotid	Inferior petrosal sinus
Semilunar ganglion of trigeminal (C.N. V)	Middle meningeal vessels
Tympanic branch of glossopharyngeal (C.N. IX)	Tympanic branch of maxillary artery
Auricular branch of vagus (C.N. X)	Internal auditory branch of basilar artery
	Internal cochlear branches of jugular

base of the skull around the vessels and nerves to join the intracranial dura.³³ Extradural restrictions may arise from muscle or visceral fascia envelopes from superficial fascias just deep to the skin or from any of the other fascial layers.⁴³ Quite often, abnormal tension from peripheral fascias enters via the dural sleeves that accompany spinal nerve roots from or to the spinal cord and to or from the transverse foramina of the vertebral spine.⁴³

The exact pathway to dural membrane tension and temporal bone restriction may vary considerably. Common restrictions include direct osseous impaction at the temporo-occipital suture or tension on muscles crossing the suture, thoracic inlet tension, respiratory diaphragm tension, strain on the sphenoid, and compression of the occipital condyles into the transverse process of the atlas.

Other restrictions found by this author to cause asymmetric temporal bone movement include a restriction of the hyoid bone with tight muscle connections to the mastoid process; compression of the vomer into the rostrum of the sphenoid; dural twisting at the thoracic-lumbar area transmitted into the tentorial membrane, producing a rhythmic torsion and side bending of the temporal bones; pyloric spasms apparently due to anxiety, which pulled the temporal bones out of sync; and a radical hysterectomy transmitting pelvic diaphragm tension into the cranium.

The value of craniosacral therapy is that it can identify seemingly esoteric and unsuspected structural abnormalities that can lead to vertigo with no apparent cause under traditional diagnostic techniques. It is usually easy for a skilled therapist to locate and release structural restrictions in the body once asymmetrical temporal motion has been found. Upledger once relieved a case of vertigo by tracing the cause of a jammed left temporal bone from an old knee and ankle injury through the pelvis and spine and into the cranium.⁴⁴

Since connective tissue restrictions from various places in the body can be transmitted into the dural tube, external or internal stressors can cause variable tension on the dura, locally or from a distance. Once a critical structural imbalance has been created, any one of these stressors (such as venous pressure changes, muscle tension, organic dysfunction, menstruation, allergies, or emotional disturbance) may trigger acute symptoms.

CONCLUSION

Clinical experience suggests that craniosacral therapy is a powerful evaluative and treatment modality for vertigo patients who have not found relief from medical treatments. A narrative review of literature describes and supports a theoretical link between dysfunction of the craniosacral system and vertigo. Dysfunction of the craniosacral system may include osseous, dural membrane, and fascial restrictions leading to asymmetric temporal bone movement and hence vertigo. Clinical trials are necessary not only to verify that craniosacral therapy is an effective treatment but also to determine the full range of symptoms and medical diagnoses for which craniosacral therapy is beneficial. These studies ought to be performed at vestibular rehabilitation or hearing and balance centers that see large numbers of patients with a variety of symptoms and established medical diagnoses. Initially, all patients with any kind of non-life-threatening dizziness or vertigo should be tested for temporal bone asymmetry. Nonspecific dizziness and vertigo, posttraumatic vertigo, positional vertigo, recurrent benign vestibulopathy, migraine vertigo, and Ménière's disease are among the diagnoses that could be evaluated for temporal bone misalignment. Results of craniosacral therapy on appropriate patients could then be evaluated and tested against standard rehabilitation techniques and controls.

Care must be taken in selecting a craniosacral therapist who has the sufficient level of skill to accurately assess and treat temporal bone misalignment, including the ability to palpate dural membrane and fascial restrictions, which may affect the temporal bones from anywhere in the body. The presence of temporal bone motion asymmetry provides a specific structural marker that is both predictive of vertigo and indicative of a positive prognosis; therefore, craniosacral therapy could reduce the amount of laboratory testing, neuroimaging, and other low-yield tests without adversely affecting patient outcome.⁶ Because of its efficiency in skilled hands, craniosacral therapy has the potential to greatly reduce the amount of time, money, and misery that vertigo often involves, at least among this class of identifiable patients.

Acknowledgments

I would like to thank Gene Miller, CST-D, for critical feedback and unending support and encouragement; Ellen McKay for invaluable critique and proofreading; and Penny Rhodes, CST-D, for insightful commentary.

REFERENCES

1. Sloan PD, Coeytaux RR, Beck RS, Dallara J. Dizziness: state of the science. *Ann Intern Med.* 2001;134(9 Pt 2):823-832.
2. Newman-Toker DE, Cannon LM, Stofferahn ME, Rothman RE, Hsieh YH, Zee DS. Imprecision in patient reports of dizziness symptom quality: a cross-sectional study conducted in an acute care setting. *Mayo Clin Proc.* 2007;82(11):1329-1340.
3. Hanley K, O'Dowd T, Considine N. A systematic review of vertigo in primary care. *Br J Gen Pract.* 2001;51(469):666-671.
4. Kroenke K, Arrington ME, Mangelsdorff AD. The prevalence of symptoms in medical outpatients and the adequacy of therapy. *Arch Intern Med.* 1990;150(8):1685-1689.
5. Hain TC, Uddin M. Pharmacological treatment of vertigo. *CNS Drugs.* 2003;17(2):85-100.
6. Kroenke K. Dizziness in primary care. *West J Med.* 1995;162(1):73-74.
7. Kroenke K, Lucas CA, Rosenberg ML, et al. Causes of persistent dizziness. A prospective study of 100 patients in ambulatory care. *Ann Intern Med.* 1992;117(11):898-904.
8. Boutin PD, Buchwald D, Robinson L, Collier AC. Use of and attitudes about alternative and complementary therapies among outpatients and physicians at a municipal hospital. *J Altern Complement Med.* 2000;6(4):335-343.
9. Crock RD, Jarjoura D, Polen A, Rutecki GW. Confronting the communication gap between conventional and alternative medicine: a survey of physicians' attitudes. *Altern Ther Health Med.* 1999;5(2):61-66.
10. Upledger JE, Vredevoogd JD. *Craniosacral Therapy*. Seattle, WA: Eastland Press; 1983.
11. Upledger J. A look inside the craniosacral system and how CST helps. *Massage Today.* Aug 2004;4(8). Available at: www.massagetoday.com/mpacms/mt/article.php?id=10979. Accessed August 21, 2009.
12. Upledger JE. *Research and Observations Support the Existence of a Craniosacral System*. West Palm Beach Gardens, FL: UI Enterprises; 1995. Available at: http://www.asi-akademie.de/Allgemein/JEU_Article_en.htm. Accessed September 5, 2009.
13. Magoun HI. The temporal bone: trouble maker in the head. *J Am Osteopath Assoc.* 1974;3(10):825-835.
14. Magoun HI. Entrapment neuropathy of the central nervous system. III. Cranial nerves V, IX, X, XI. *J Am Osteopath Assoc.* Apr 1968;67(8):889-899.
15. Upledger J. TMJ: primary problem, or tip of the iceberg? *Massage Today.* 2002;2(8). Available at: http://www.massagetoday.com/mpacms/mt/article.php?id=10531&no_pagenate=true&no_b=true. Accessed August 21, 2009.
16. Sampson WI. Homeopathic vs conventional treatment of vertigo. *Arch Otolaryngol Head Neck Surg.* 2003;129(4):497; author reply 498.
17. Bhattacharyya N, Baugh RF, Orvidas L, et al. Clinical practice guideline: benign paroxysmal positional vertigo. *Otolaryngol Head Neck Surg.* 2008;139(5 Suppl 4):S47-S81.
18. Oman CM. A heuristic mathematical model for the dynamics of sensory conflict and motion sickness. *Acta Otolaryngol Suppl.* 1982;392:1-44.
19. Dichgans J, Brandt T. Optokinetic motion sickness and pseudo-Coriolis effects induced by visual stimuli. *Acta Otolaryngol.* 1973;76(5): 339-338.
20. Moss ML, Young RW. The functional approach to craniology. *Am J Phys Anthropol.* 1960 Dec;18:281-292.
21. Jaslow CR. Mechanical properties of cranial sutures. *J Biotech.* 1990;23(4):313-321.
22. Frymann VM. A study of the rhythmic motions of the living cranium. *J Am Osteopath Assoc.* 1971;70(9):928-945.
23. Adams T, Heisey RS, Smith MC, Briner BJ. Parietal bone mobility in the anesthetized cat. *J Am Osteopath Assoc.* 1992;92(5):599-600, 603-610, 615-622.
24. Heifetz MD, Weiss W. Detection of skull expansion with increased intracranial pressure. *J Neurosurgery.* 1981;55(5):811-812.
25. Heisey SR, Adams T. Role of cranial bone mobility in cranial compliance. *Neurology.* 1993;33(5):869-876; discussion 876-877.
26. Herring SW, Teng S. Strain in the braincase and its sutures during function. *Am J Phys Anthropol.* 2000;112(4):575-593.
27. Retzlaff EW, Michael DK, Roppel RM. Cranial bone mobility. *J Am Osteopath Assoc.* 1975;74(9):869-873.
28. Michael DK, Retzlaff EW. Preliminary study of cranial bone movement in the squirrel monkey. *J Am Osteopath Assoc.* 1975;75(9):133-138.
29. Moskalenko YE, Kravchenko TI, Gaidar BV, et al. Periodic mobility of cranial bones in humans. *Human Physiol.* 1999;25(1):51-58. Available at: http://www.maik.ru/abstract/humphys/99/humphys1_99p51abs.htm. Accessed September 5, 2009.
30. Retzlaff EW, Michael D, Roppel R, Mitchell F. The structures of cranial sutures. *J Am Osteopath Assoc.* 1976;75(6):607-608.
31. Pritchard JJ, Scott JH, Girgis FG. The structure and development of the cranial and facial sutures. *J Anat.* 1956;90(1):73-86.
32. Moss ML. Experimental alteration of suture area morphology. *Anat Rec.* 1957;127(3):569-589.
33. Magoun HI. Entrapment neuropathy in the cranium. *J Am Osteopath Assoc.* 1968;67(6):643-652.
34. Retzlaff EW, Upledger JE, Mitchell FL Jr, Walsh J. Aging of cranial sutures in humans. *Anat Rec.* Mar 1979;193:663. Available at: http://www.upledger.com/pdf/article_list.pdf. Article #7903. Accessed September 5, 2009.
35. Upledger JE, Retzlaff E, Vredevoed M. Diagnosis and treatment of temporoparietal suture head pain. *Osteopath Med.* July 1978;19-26. Available at: http://www.upledger.com/pdf/article_list.pdf. Article #7807. Accessed September 5, 2009.
36. Sabini RC, Elkowitz DE. Significance of differences in patency among cranial sutures. *J Am Osteopath Assoc.* 2006;106(10):600-604.
37. Kostopoulos DC, Keramidas G. Changes in elongation of falx cerebri during craniosacral therapy techniques applied on the skull of an embalmed cadaver. *Cranio.* 1992;10(1):9-12.
38. Upledger J. Craniosacral dissection sheds new light on effects of palpation. *Massage Today.* 2002;2(2). Available at: www.massagetoday.com/mpacms/mt/article.php?id=10406. Accessed August 21, 2009.
39. Upledger J. *Craniosacral Dissection and Anatomy* [videotape]. Palm Beach Gardens, FL: Upledger Institute Inc; 2000.
40. Oleski SL, Smith GH, Crow WT. Radiographic evidence of cranial bone mobility. *Cranio.* 2002;20(1):34-38.
41. Spetzler RF, Spetzler H. Holographic interferometry applied to the study of the human skull. *J Neurosurg.* 1980;52(6):825-828.
42. Magoun HI. Entrapment neuropathy of the central nervous system. II. Cranial nerves I-IV, VI-VIII, XII. *J Am Osteopath Assoc.* 1968;67(7):779-787.
43. Upledger J. Connective tissue leads to the core of good health. *Massage Today.* 2004;4(3). Available at: www.massagetoday.com/mpacms/mt/article.php?id=10893. Accessed August 21, 2009.
44. Murphy J. Olympic diver sinks vertigo with craniosacral therapy. *Advance.* October 21, 1996. Available at: <http://physical-therapy.advanceweb.com/Article/Olympic-Diver-Sinks-Vertigo.aspx>. Accessed August 21, 2009.

Transform your practice and your life.

Join us in Saybrook's College of Mind-Body Medicine. Work with our Dean, James S. Gordon, MD, a pioneer in mind-body and integrative medicine, and our outstanding, nationally-recognized faculty.

MS, PhD, and Certificate Options

Apply now for spring, summer, or fall 2010.
Scholarships and financial aid available.

Grounded in the understanding that self-awareness, self-care and mutual help are crucial to the prevention and treatment of all chronic illness and to the fulfillment of our human potential.

SAYBROOK
GRADUATE SCHOOL • RESEARCH CENTER

GRADUATE EDUCATION
FOR A HUMANE AND
SUSTAINABLE FUTURE

WASC Accredited

Tel: 800 825-4480 www.saybrook.edu admissions@saybrook.edu